

Percutaneous Endoscopic Lumbar Discectomy for Recurrent Disc Herniation: Surgical Technique, Outcome, and Prognostic Factors of 43 Consecutive Cases

Yong Ahn, MD,* Sang-Ho Lee, MD, PhD,* Woo-Min Park, MD,* Ho-Yeon Lee, MD, PhD,*
Song-Woo Shin, PhD,* and Ho-Yeong Kang, MD†

Study Design. A retrospective study of 43 consecutive patients who underwent percutaneous endoscopic lumbar discectomy for recurrent disc herniation.

Objectives. To evaluate the efficacy of endoscopic discectomy for recurrent disc herniations and to determine the prognostic factors affecting surgical outcome.

Summary of Background Data. Repeated open discectomy with or without fusion has been the most common procedure for a recurrent lumbar disc herniation. There have been no reports published on the feasibility and prognostic factors of the endoscopic discectomy for recurrent disc herniation.

Methods. The inclusion criteria were recurrent disc herniations at the same level, regardless of side, with a pain-free interval longer than 6 months after the conventional open discectomy. Posterolateral endoscopic laser-assisted disc excisions were performed under local anesthesia.

Results. The mean follow-up period was 31 months (24–39 months). Based on the MacNab criteria, 81.4% showed excellent or good outcomes. The mean visual analog scale decreased from 8.72 ± 1.20 to 2.58 ± 1.55 ($P < 0.0001$). In our series, better outcomes were obtained in patients younger than 40 years ($P = 0.035$), patients with duration of symptoms of less than 3 months ($P = 0.028$), and patients without concurrent lateral recess stenosis ($P = 0.007$).

Conclusions. Percutaneous endoscopic lumbar discectomy is effective for recurrent disc herniation in selected cases. The posterolateral approach through unscarred virgin tissue can prevent nerve injury and could preserve the spinal stability. Both foraminal and intracanalicular portions can be decompressed simultaneously.

Key words: recurrent disc herniation, posterolateral, transforaminal, endoscopic discectomy. **Spine** 2004;29:E326–E332

tomy through the same approach as the initial surgery.^{1,2,4–8,14,15,21,27,28,32} Although many authors have recommended a repeated discectomy, it could produce less satisfactory results than the primary operations,^{6–8,21} and approach-related complications could be apparent. Scar tissue makes a repeated discectomy more difficult, increasing the risk of dural tear or nerve injury.^{17,21,31,35} Further removal of posterior structures, including the facet joint, could increase the risk of segmental instability.^{28,34}

In recent years, a number of percutaneous endoscopic procedures for lumbar disc herniations have been developed in terms of minimally invasive spine surgery, with clinical outcomes comparable to those of conventional open surgery.^{13,16,18–20,22,24,37,38} In fact, the concept of the percutaneous endoscopic lumbar discectomy (PELD) has already shifted from an indirect central decompression to a direct epidural targeted fragmentectomy. However, it has not been determined whether PELD is also effective for recurrent herniation. There have been few previous studies on the outcomes of endoscopic discectomy for recurrent lumbar disc herniation.³⁸

The purpose of this study was to evaluate the efficacy of PELD for recurrent disc herniation and to determine the prognostic factors affecting the outcome.

■ Materials and Methods

Patient Population and Outcome Evaluation. A retrospective review was performed on 43 consecutive patients who underwent PELD for recurrent disc herniation after the conventional open discectomy. The inclusion criteria of this study were as follows: 1) a previous episode of conventional open discectomy resulting from lumbar disc herniation; 2) recurrent radicular pain after a pain-free interval longer than 6 months; 3) recurrent disc herniation at the same level, regardless of the side, verified by the radiologic studies; and 4) failure of extensive conservative therapies. In contrast, cases with calcified fragments, chronic discogenic back pain, definite segmental instability including spondylolisthesis and severe neurologic deficit were excluded.

The surgical outcomes were assessed using the Macnab²³ criteria and visual analog scales (VAS). A successful outcome was defined as excellent or good based on the MacNab criteria. One radiologist, blinded to the study design, made a radiologic diagnosis and analysis. Recurrent disc herniation was seen as an iso- or hypointense soft tissue mass on magnetic resonance imaging, compressed the nerve root and/or dural sac, and demonstrated a lack of early central contrast enhancement,

Recurrent lumbar disc herniation after the conventional discectomy has been reported in 5–11% of patients, most of whom have been treated with a repeated discectomy.

From the Divisions of *Neurosurgery and †Diagnostic Radiology, Wooridul Spine Hospital, Seoul, Korea.

Acknowledgment date: June 19, 2003. First revision date: October 17, 2003. Second revision date: November 10, 2003. Acceptance date: November 17, 2003.

The manuscript submitted does not contain information about medical device(s)/drug(s).

No funds were received in support of this work. No benefits in any form have been or will be received from a commercial party related directly or indirectly to the subject of this manuscript.

Address correspondence to Yong Ahn, MD, Division of Neurosurgery, Wooridul Spine Hospital, 47-4 Chungdam-dong, Kangnam-gu, Seoul 135-100, Korea; E-mail: ns-ay@hanmail.net

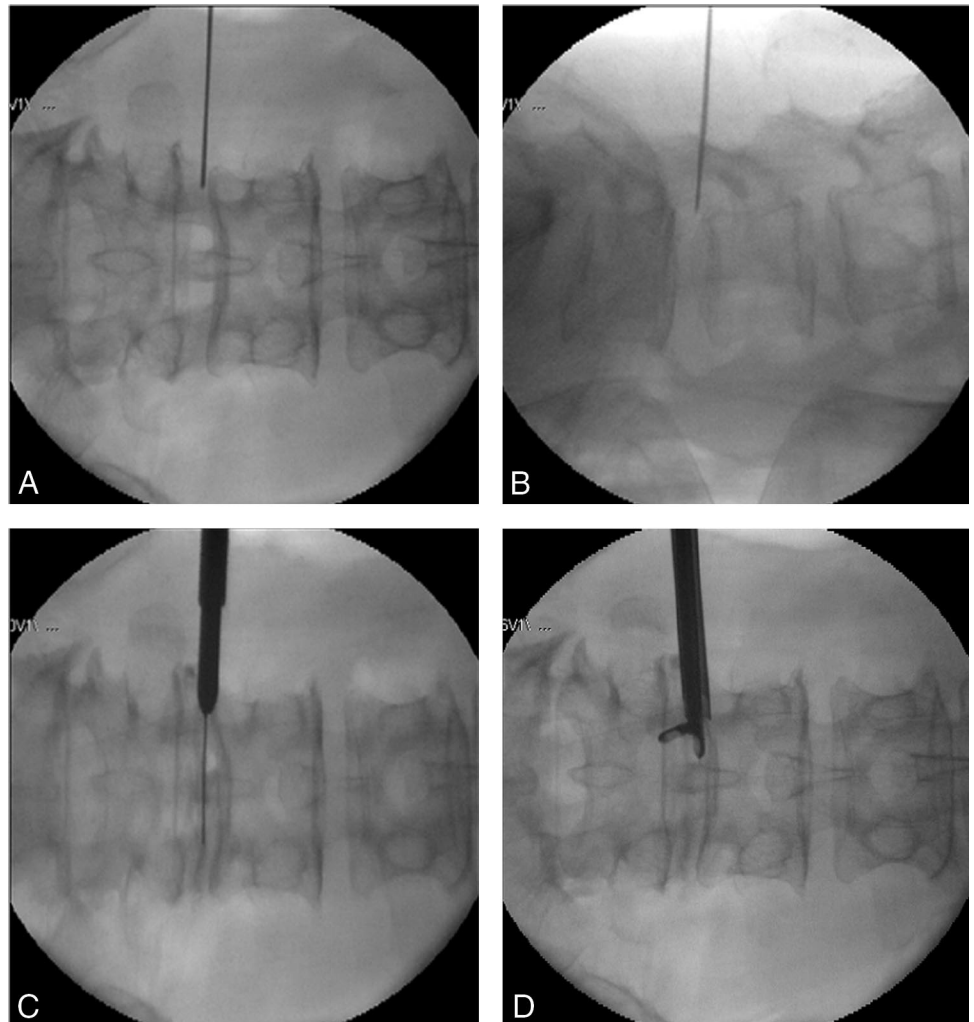


Figure 1. (A–D) The operative procedure from the fluoroscopic view. The needle is positioned at the midpedicular line on the anteroposterior view (A) and at the posterior vertebral line on lateral view (B). The needle is replaced by a guide wire followed by an obturator and a final working cannula in that sequence (C). A manual discectomy is then performed in the subannular region under fluoroscopic guidance in a conscious state (D).

whereas epidural fibrosis showed homogeneous enhancement.^{9,29} Statistical analysis was performed using Fisher exact test and *t* test, with two-tailed *P* values less than 0.05 considered significant.

Surgical Technique. The fundamental target of this technique is to remove the offending herniated disc material through posterolateral unscarred tissue planes. Under local anesthesia, the patient is placed in the prone position on a radiolucent table with mild flexion of the back.

The skin entry point is typically approximately 8 to 11 cm from the midline. To determine the appropriate entry point, preoperative imaging studies and intraoperative fluoroscopy should be performed. An 18-gauge spinal needle is inserted after infiltration of local anesthetics. The needle tip is positioned at the midpedicular line in the anteroposterior projection and on the posterior vertebral line in the lateral projection (Figure 1A). At this time, a transforaminal epidural infiltration through the spinal needle with 0.5% lidocaine is recommended to effectively prevent the approach-related pain and discomfort. After insertion of the needle, an intraoperative discography is performed with a mixture of 6 mL of contrast media and 1 mL of indigo carmine. The pathologic nucleus and annular fissure can then be stained for easy discrimination through both the fluoroscope and endoscope.

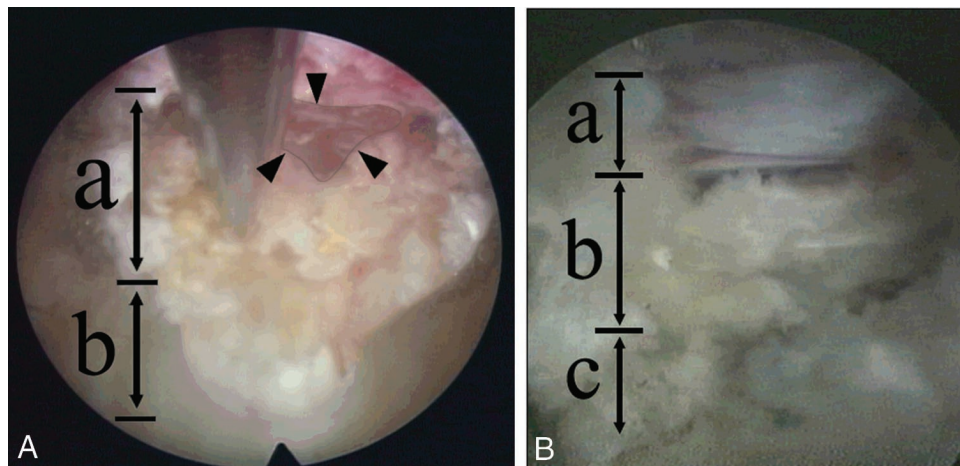
A guide wire is then inserted through the needle into the

annulus and a small stab incision is made at the entry site of the needle. After the needle is withdrawn, a tapered cannulated obturator is slid over the guide wire and introduced gently into the foramen. The tip of the obturator should be held firmly by foraminal bony structures and should contact the annular surface (Figure 1C). The next step is the introduction of a beveled working cannula over the obturator. The bevel-ended, oval-shaped working cannula guarantees a safer and less painful transforaminal annular contact than the standard working cannula. After the obturator is withdrawn, a 5.8 × 5.1-mm ellipsoidal endoscope, with an eccentrically placed 2.7-mm working channel and two irrigation channels, is inserted. Through the endoscope, the surgeon can see the surface of the blue-stained annulus and a section of epidural fat. In a recurrent disc herniation, inflamed fibrotic tissues are often seen instead of the epidural fat. The annular surface is clearly defined after trimming the epidural fat or other soft tissue debris using a bipolar coagulator.

After confirming the safety of the working space, the discectomy can commence with an annulotomy. A small annulotomy cutter cuts the annulus in a circular fashion to make a working intradiscal tunnel. Through this tunnel, a manual discectomy is then performed in the subannular region with fluoroscopic guidance (Figure 1D).

An initial endoscopic exploration is then made from the posterolateral subarticular region. The ideal endoscopic visu-

Figure 2. Intraoperative endoscopic view. (A) The intradiscal undersurface of the annulus (a) is demonstrated. After the removal of the herniated disc, a large annular fissure (demarcated by arrowheads) is well visualized. Through this fissure, the epidural pulsation and dural sac can be visualized. The remaining nucleus pulposus (b) is also demonstrated. (B) At the final step, the anatomic details are well demonstrated, including the traversing root (a), the posterior longitudinal ligament (b), and the remaining nucleus pulposus (c).



alization consists of the epidural part in the upper half and the intradiscal space in the lower half of the overview. The surgeon can see the “layers” through the transforaminal endoscopic window: layers of superior facet, epidural fat, inflamed epidural fibrotic tissues, posterior longitudinal ligaments, and disc material. The herniated disc and fibrotic scar tissues are then removed using endoscopic forceps and a side-firing, Holmium yttrium-aluminum-garnet (Ho:YAG) laser. The soft herniated disc is usually stained blue by indigo carmine, easily movable, and can be well vaporized by the laser, whereas the whitish epidural scar is not stained but is tenacious in nature. If the tough fibrotic adhesions anchor the herniated fragment, the side-firing Ho:YAG laser and cutting forceps widen the annular fissure. Once the fibrotic anchorage has been loosened and the annular fissure is opened widely, the blue-stained herniated disc material can then be visualized and easily removed by the endoscopic forceps. As the intradiscal-working cavity widens, and the back muscle tension relaxes, the angle of the endoscope can become more horizontal, thereby pivoting on the foramen. With this levering technique, the surgeon can examine the full undersurface of the annulus and even remove the epidural herniated hernia fragments (Figure 2A). Finally, the intradiscal and epidural dissection are performed, where the decompressed traversing root and dural sac are identified (Figure 2B). When all the herniated disc material and fibrotic tissues have been removed, the endoscope is withdrawn and a sterile dressing is applied with a one-point subcutaneous suture.

All patients are permitted to go home within 24 hours if there are no postoperative problems.

■ Results

The 43 patients who met the inclusion criteria underwent PELD. The mean follow-up period was 31 months (range, 24–39 months). There were 32 (74.4%) males and 11 (25.6%) females with a mean age of 45.5 years (range, 22–72 years). The mean pain-free interval after the previous surgery was 63 months, ranging from 6 to 186 months. The anatomic zones of recurrence were central in seven patients (16.3%), subarticular in 31 (72.1%), foraminal in four (9.3%), and extraforaminal in one (2.3%). There were 35 (81.4%) patients with recurrent disc herniations on the same side as previous surgery and eight (18.6%) with on the opposite side. The levels of recurrence were L3–L4 in two (4.7%) cases,

L4–L5 in 35 (81.4%), and L5–S1 in six (13.9%). The mean operative time was 51 minutes, ranging from 25 to 100 minutes. The demographic findings are summarized in Table 1.

Based on the MacNab criteria, the surgical outcomes were rated as follows: excellent in 12 patients (27.9%), good in 23 (53.5%), fair in six (13.9%), and poor in two (4.7%). Therefore, the percentage of successful outcomes was 81.4%, whereas the rate of improvement was 95.3%. The preoperative mean VAS was 8.72 ± 1.20 , which decreased to 2.58 ± 1.55 at the final follow up ($P < 0.0001$). One of the two patients, who rated as poor, underwent subsequent open microdiscectomy because of incomplete decompression. The other received extensive

Table 1. Demographic Characteristics of 43 Patients

| Data | No. | Percent |
|---|-----|---------|
| Sex | | |
| Male | 32 | 74.4 |
| Female | 11 | 25.6 |
| Age | | |
| <30 yr | 7 | 16.3 |
| 31–40 yr | 8 | 18.6 |
| 41–50 yr | 16 | 37.2 |
| >50 yr | 12 | 27.9 |
| Duration of symptoms | | |
| <3 mos | 31 | 72.1 |
| 3–6 mos | 7 | 16.3 |
| >6 mos | 5 | 11.6 |
| Pain-free interval after previous surgery | | |
| <1 yr | 12 | 27.9 |
| 1–5 yr | 12 | 27.9 |
| 5–10 yr | 9 | 20.9 |
| >10 yr | 10 | 23.3 |
| Zone of recurrence | | |
| Central | 7 | 16.3 |
| Subarticular | 31 | 72.1 |
| Foraminal | 4 | 9.3 |
| Extraforaminal | 1 | 2.3 |
| Side of recurrence | | |
| Same side | 35 | 81.4 |
| Opposite side | 8 | 18.6 |
| Spinal level involved | | |
| L3–L4 | 2 | 4.7 |
| L4–L5 | 35 | 81.4 |
| L5–S1 | 6 | 13.9 |

Table 2. Clinical factors affecting surgical outcome

| Variable | Total No. | Successful Outcome | | P Value |
|-----------------------------|-----------|--------------------|---------|---------|
| | | No. | Percent | |
| Male | 32 | 27 | 84.4 | NS |
| Female | 11 | 8 | 72.7 | |
| Age <40 yrs | 15 | 15 | 100.0 | |
| Age ≥40 yrs | 28 | 20 | 71.4 | 0.036 |
| Leg pain alone | 17 | 15 | 88.2 | |
| Leg pain with back pain | 26 | 20 | 76.9 | |
| Duration of symptoms <3 mos | 31 | 28 | 90.3 | 0.028 |
| Duration of symptoms ≥3 mos | 12 | 7 | 58.3 | |
| Pain-free interval <1 yr | 12 | 11 | 91.7 | |
| Pain-free interval ≥1 yr | 31 | 24 | 77.4 | NS |
| Motor deficit | 19 | 14 | 73.7 | |
| Normal motor function | 24 | 21 | 87.5 | |
| SLR ≤80 | 29 | 24 | 82.8 | NS |
| SLR ≥80 | 14 | 11 | 78.6 | |

NS = not significant.

physical therapy and repeated epidural injection therapy. Complication was transient dysesthesia, which improved within 6 months in two patients.

Statistical Analysis of Prognostic Factors.

Patients' age and duration of symptoms were strongly related with surgical outcome. Patients younger than 40 years showed better outcomes ($P = 0.036$). Cases with duration of symptoms of less than 3 months also had a tendency to have successful outcomes ($P = 0.028$). There were no significant influences from other factors, including gender, chief complaints, pain-free interval after the previous surgery, preoperative neurologic deficit, and presence of Lasègue's sign (Table 2).

In consideration of the radiologic findings, the presence of concurrent lateral recess stenosis was the only factor affecting the outcome. The lateral recess is bordered laterally by the pedicle, dorsally by the horizontal segment of the superior facet, and ventrally by the posterior surface of the vertebral body. The ventral-to-dorsal diameter of lateral recess can be delineated by computed tomography scan using the bone window setting (Figure 3A). The lateral recess stenosis was defined as a lateral recess measurement of less than 3 mm.^{3,10,25} Six (13.9%) of 43 patients had concurrent lateral recess stenosis resulting from facet hypertrophy, severe shoulder osteophytes, or a calcified remaining ligamentum flavum.

Table 3. Radiologic Factors Affecting Surgical Outcome

| Variable | Total No. | Successful Outcome | | P Value |
|-----------------------------|-----------|--------------------|---------|---------|
| | | No. | Percent | |
| Ipsilateral recurrence | 35 | 30 | 85.7 | NS |
| Contralateral recurrence | 8 | 5 | 62.5 | |
| Intracanalicular | 38 | 32 | 84.2 | |
| Foraminal/extraforaminal | 5 | 3 | 60.0 | NS |
| L4-L5 or above | 37 | 31 | 83.8 | |
| L5-S1 | 6 | 4 | 66.7 | |
| Protrusion | 14 | 10 | 71.4 | NS |
| Extrusion | 29 | 25 | 86.2 | |
| Canal compromise ≤1/3 | 33 | 26 | 78.8 | |
| Canal compromise ≥1/3 | 10 | 9 | 90.0 | 0.007 |
| Lateral recess stenosis (+) | 6 | 2 | 33.3 | |
| Lateral recess stenosis (−) | 37 | 33 | 89.2 | |

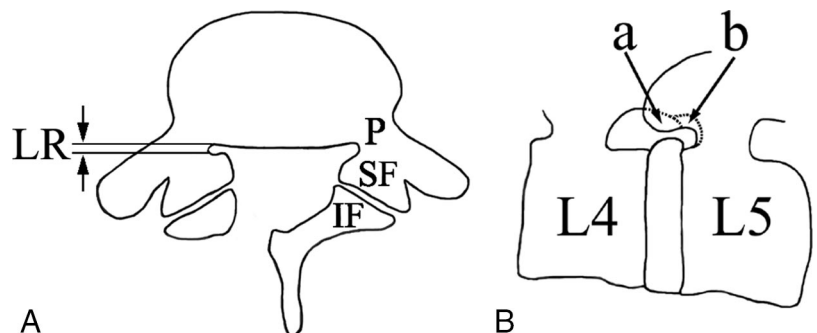
NS = not significant.

der osteophytes, or a calcified remaining ligamentum flavum. Among these six with lateral recess stenosis, only two (33.3%) had successful outcomes, whereas 33 (89.2%) of the remaining 37 without lateral recess stenosis had successful outcomes ($P = 0.007$). However, other radiologic indicators such as the side, the zone, the level and the nature of recurrence, and the degree of canal compromise did not have a significant influence on surgical outcomes (Table 3).

Discussion

A posterior repeated discectomy has been considered the treatment of choice for recurrent lumbar disc herniations.^{1,2,4,6-8,14,21,28,32} However, the following problems can make a repeated discectomy more demanding or could affect the clinical outcome. First, epidural or perineural scar tissue could disturb the dissection in the posterior approach, increasing the risk of dural tear or nerve injury.^{17,21,31,35} Second, an extended muscle splitting dissection and laminectomy with partial facetectomy could aggravate segmental instability and cause postoperative low back pain.^{28,34} Third, a posterior re-exploration alone cannot resolve the concomitant foraminal disc herniation or stenosis, which frequently develops after the first surgery.³³ Consequently, a repeated discectomy should often be combined with an additional far-lateral approach or a wide facetectomy and fusion.

Figure 3. Lateral recess stenosis. (A) The lateral recess stenosis was defined as a lateral recess measurement of less than 3 mm on the bone window setting of the spiral computed tomography scan. The schematic drawing demonstrates the lateral recess (LR), superior facet (SF), inferior facet (IF), and pedicle (P). (B) The tip of the superior facet (a) can be easily removed by a bone reamer and a side-firing Ho:YAG laser, whereas the horizontal part of the superior facet, medial to the pedicle (b), is relatively difficult to remove because this part is thicker and harder than the tip of the superior facet. In this study, patients with concurrent lateral recess bony stenosis had a relatively low success rate ($P = 0.007$).



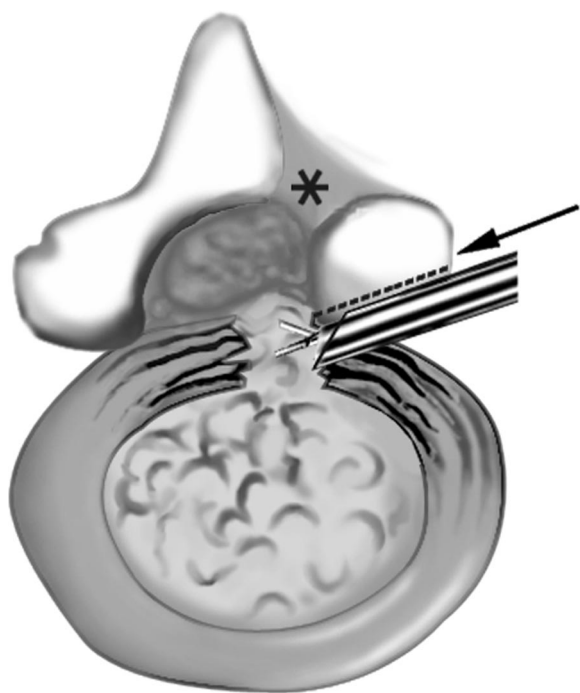


Figure 4. Advantages of a percutaneous endoscopic lumbar discectomy for a recurrent disc herniation. The posterolateral approach (arrow) through unscarred virgin tissue can prevent nerve injury. It does not damage the posterior paraspinal structures (*) and could preserve the spinal stability. Simultaneous decompression on both the foraminal and intracanalicular portions is feasible by a transforaminal approach (dotted line). The tip of the hypertrophic superior facet can be undercut using a bone reamer and a side-firing Ho:YAG laser.

PELD Could Be the Solution to These Problems.

A repeated discectomy requires direct dissection of the epidural fibrosis or perineural scar tissue followed by retraction of the scarred nerve roots and dural sac. Ebeling *et al*⁶ reported a complication rate of 13% after repeated discectomy; dural tears and infections were the most common problems. PELD provides an approach through unscarred virgin tissue. Therefore, the surgeon can approach the target site safely without demanding dissection of the fibrotic scar tissues, and the potential risk of dural tear, nerve injury, or infection could also be decreased (Figure 4). Being continuously conscious, patients can be monitored by surgeons for any inadvertent physical trauma to the nervous structures.³⁸ Surgeons can also monitor whether the radicular pain improves during the procedure.

With a repeated discectomy, splitting of the muscle and further removal of the lamina and facet are always necessary. Postoperative segmental instability could thereby be caused or aggravated. After the conventional discectomy, 11% to 15% of postoperative disabling low back pain incidences have been reported.^{5,11,12,30,36} With a reoperation, the risk of postoperative low back pain could increase. Moreover, in the case of a contralateral recurrent disc herniation, the removal of the contralateral posterior structures and disc could also in-

crease the potential risk of postoperative segmental instability. PELD does not damage the posterior paraspinal structures (laminae, facets, ligaments, and muscles) and could preserve the spinal stability (Figure 4). Osman *et al*²⁶ reported a comparative study between transforaminal and posterior decompressions of the lumbar spine, in which a significant increase in the extension and axial rotation flexibilities were noted after the posterior decompression. In contrast, there was no flexibility change after the transforaminal decompression because the anatomic integrity of the spine was preserved.

The transforaminal posterolateral approach enables the simultaneous decompression of both the foraminal and intracanalicular portions. Postoperative foraminal stenosis or foraminal disc herniation has been considered as a major cause of failed back surgery syndrome.³³ Postoperative degenerative changes after the conventional discectomy could arise with time. Gradual disc space subsidence and impingement of the superior facet could result in newly developed back pain or radicular leg pain. Moreover, once a recurrent disc herniation has occurred, the foraminal narrowing could aggravate radicular leg pain. Because the foraminal portion can be exposed in the course of the posterolateral approach, adequate foraminal decompression can be easily accomplished with PELD. The tip of the hypertrophic superior facet was undercut using a bone reamer and a side-firing Ho:YAG laser (Figure 4). The foraminal disc herniation or redundant annulus was also removed using the forceps and laser. This foraminal decompression has three benefits. First, the direct mechanical widening of the foramen can decompress the exiting nerve root. Second, sophisticated adhesiolysis of the epidural or perineural fibrosis can be performed through the foramen extended to the lateral recess. Third, it provides enough working space needed for the excision of the recurrent disc herniation in the paracentral region. Osman *et al*²⁶ noted that a transforaminal decompression produced a significantly larger increase in the intervertebral foraminal area than a posterior decompression (45.5% vs. 34.2% increase). Therefore, they suggested that endoscopic transforaminal decompression was a feasible alternative to the conventional posterior approach.

Although satisfactory clinical outcomes have been demonstrated with PELD, it requires a highly experienced endoscopic surgeon. The learning curve is relatively steep, and the clinical outcomes could be affected by the surgeon's technique. If the hernia mass is overtly calcified or combined with severe spinal stenosis, the effect of an endoscopic removal could be limited. If there are severe neurologic deficits like cauda equina syndrome or foot drop, an open reexploration is mandatory. When definite segmental instability causes severe low back pain, an endoscopic discectomy alone has a high risk of failure also. In these cases, a supplementary fusion procedure should be considered.

Although several authors have reported the benefits of a transforaminal endoscopic discectomy, statistical studies of the factors affecting the outcome are rare.²² In our study, age was one of the major clinical factors affecting the outcome. All the patients younger than 40 years showed successful outcomes, whereas only 71.4% of patients older than 40 did so ($P = 0.036$). This finding corresponds closely to that of previous studies on conventional lumbar disc surgery.^{12,30,36} The authors, however, do not believe that this minimally invasive technique is only suitable for younger patients. PELD can be an appropriate treatment method for older patients with concurrent serious medical illnesses, which entail a high risk with conventional surgery under general anesthesia. Duration of symptoms was also important in predicting the surgical outcome. Patients with duration of symptoms of less than 3 months had better outcomes than those of more than 3 months (90.3% vs. 58.3%, $P = 0.028$). This finding indicates that a more recent reherniation is easier to remove and that the nerve root compromise is also subject to a reversal. The presence of concurrent lateral recess stenosis was the major radiologic factor predicting a poor outcome. The rate of successful outcomes was significantly different between "nonstenotic recurrence" and "stenotic recurrence" (89.2% vs. 33.3%, $P = 0.007$). Considering the technique in detail, the tip of the superior facet can be easily removed by a bone reamer and a side-firing Ho:YAG laser. However, the horizontal part of the superior facet, medial to the pedicle, is relatively difficult to remove because this part is thicker and harder than the tip of the superior facet (Figure 3B). The foraminal narrowing, resulting from facet impingement or soft tissue compression, for the exiting nerve root can be controlled. The soft components at the lateral recess area such as the disc herniation or scar tissues are also controllable. Contrarily, if there is concurrent lateral recess bony stenosis, especially of the medial part of the pedicle, it is difficult to decompress this portion. The authors, therefore, think the poor outcome of the concurrent lateral recess bony stenosis group indicates the current technical limitation to be solved.

When treating patients with a recurrent lumbar disc herniation, one of the most important factors is patient selection. The authors do not believe that all recurrences can be treated with minimally invasive procedures such as PELD. In the case of a severe neurologic deficit or severe stenosis, a repeated conventional discectomy could be adequate. Sometimes, an additional fusion procedure could be necessary. Based on the results of this study, the authors suggest the following indications of PELD for recurrent lumbar disc herniations: 1) a soft disc herniation, 2) the absence of severe neurologic deficit, 3) the absence of concurrent lateral recess stenosis, 4) definite sciatica with duration of symptoms shorter than 3 months after the recurrence, and 5) patients under 40 years or older patients with concurrent, serious, or med-

ical illnesses who cannot tolerate conventional surgery under general anesthesia.

■ Key Points

- Percutaneous endoscopic lumbar discectomy is useful for recurrent disc herniation in selected cases.
- The posterolateral approach through unscarred tissue allows surgeons to remove the recurrent herniated discs while preventing nerve injury and preserving spinal stability.
- Both foraminal and intracanalicular portions can be decompressed simultaneously through the transforaminal approach.
- Patients younger than 40 years, patients with duration of symptoms of less than 3 months, and patients without concurrent lateral recess stenosis tended to have better outcomes.

Acknowledgments

The authors thank In-Sook Cho, Hye-Seon Lee, Chang-Ho Kim, and James Lee for the help in preparing the manuscript and figures.

References

1. Cinotti G, Gumina S, Giannicola G, et al. Contralateral recurrent lumbar disc herniation. Results of discectomy compared with those in primary herniation. *Spine* 1999;24:800–6.
2. Cinotti G, Roysam GS, Eisenstein SM, et al. Ipsilateral recurrent lumbar disc herniation. A prospective, controlled study. *J Bone Joint Surg [Br]* 1998;80:825–32.
3. Ciric I, Mikhael MA. Lumbar spinal-lateral recess stenosis. *Neurol Clin* 1985;3:417–23.
4. Connolly ES. Surgery for recurrent lumbar disc herniation. *Clin Neurosurg* 1992;39:211–6.
5. DePalma AF, Rothman RH. Surgery of the lumbar spine. *Clin Orthop* 1969;63:162–70.
6. Ebeling U, Kalbarczyk H, Reulen HJ. Microsurgical reoperation following lumbar disc surgery. Timing, surgical findings, and outcome in 92 patients. *J Neurosurg* 1989;70:397–404.
7. Ebeling U, Reichenberg W, Reulen HJ. Results of microsurgical lumbar discectomy. Review of 485 patients. *Acta Neurochir Wien* 1986;81:45–52.
8. Fandino J, Botana C, Viladrich A, et al. Reoperation after lumbar disc surgery: results in 130 cases. *Acta Neurochir Wien* 1993;122:102–4.
9. Fardon DF, Milette PC. Nomenclature and classification of lumbar disc pathology. Recommendations of the Combined task Forces of the North American Spine Society, American Society of Spine Radiology, and American Society of Neuroradiology. *Spine* 2001;26:E93–E113.
10. Garfin SR, Rydevik BL, Lipson SJ, et al. Spinal stenosis: pathophysiology. In: Herkowitz HN, Garfin SR, Balderston RA, et al., eds. *Rothman-Simeone: The Spine*, 4th ed. Philadelphia: WB Saunders; 1999:779–96.
11. Hakelius A. Prognosis in sciatica. A clinical follow-up of surgical and non-surgical treatment. *Acta Orthop Scand Suppl* 1970;129:1–76.
12. Hanley EN Jr, Shapiro DE. The development of low-back pain after excision of a lumbar disc. *J Bone Joint Surg [Am]* 1989;71:719–21.
13. Hermantin FU, Peters T, Quartararo L, et al. A prospective, randomized study comparing the results of open discectomy with those of video-assisted arthroscopic microdiscectomy. *J Bone Joint Surg [Am]* 1999;81:958–65.
14. Herron L. Recurrent lumbar disc herniation: results of repeat laminectomy and discectomy. *J Spinal Disord* 1994;7:161–6.
15. Jackson RK. The long-term effects of wide laminectomy for lumbar disc excision: a review of 130 patients. *J Bone Joint Surg [Br]* 1971;53:609–16.
16. Kambin P, Casey K, O'Brien E, et al. Transforaminal arthroscopic decompression of lateral recess stenosis. *J Neurosurg* 1996;84:462–7.
17. Kim SS, Michelsen CB. Revision surgery for failed back surgery syndrome. *Spine* 1992;17:957–60.

18. Knight MT, Ellison DR, Goswami A, et al. Review of safety in endoscopic laser foraminoplasty for the management of back pain. *J Clin Laser Med Surg* 2001;19:147–57.
19. Knight MT, Goswami A, Patko JT, et al. Endoscopic foraminoplasty: a prospective study on 250 consecutive patients with independent evaluation. *J Clin Laser Med Surg* 2001;19:73–81.
20. Knight MT, Vajda A, Jakab GV, et al. Endoscopic laser foraminoplasty on the lumbar spine—early experience. *Minim Invasive Neurosurg* 1998;41:5–9.
21. Law JD, Lehman RAW, Kirsch WM. Reoperation after lumbar intervertebral disc surgery. *J Neurosurg* 1978;48:259–63.
22. Lew SM, Mehalic TF, Fagone KL. Transforaminal percutaneous endoscopic discectomy in the treatment of far-lateral and foraminal lumbar disc herniations. *J Neurosurg (Spine 2)* 2001;94:216–20.
23. MacNab I. Negative disc exploration: An analysis of the causes of nerve root involvement in sixty-eight patients. *J Bone Joint Surg [Am]* 1971;53:891–903.
24. Mayer HM, Brock M. Percutaneous endoscopic lumbar discectomy (PELD). *Neurosurg Rev* 1993;16:115–20.
25. Mikhael MA, Ciric I, Tarkington JA, et al. Neuroradiological evaluation of lateral recess syndrome. *Radiology* 1981;140:97–107.
26. Osman SG, Nibu K, Panjabi MM, et al. Transforaminal and posterior decompressions of the lumbar spine. A comparative study of stability and intervertebral foramen area. *Spine* 1997;22:1690–5.
27. O'Sullivan MG, Connolly AE, Buckley TF. Recurrent lumbar disc protrusion. *Br J Neurosurg* 1990;4:319–25.
28. Ozgen S, Naderi S, Ozgen MM, et al. Findings and outcome of revision lumbar disc surgery. *J Spinal Disord* 1999;12:287–92.
29. Picard L, Bracard S, Prere J, et al. Postoperative spine. In: Manelfe C, ed. *Imaging of the Spine and Spinal Cord*. New York: Raven Press; 1992:811–49.
30. Salenius P, Laurent LE. Results of operative treatment of lumbar disc herniation. A survey of 886 patients. *Acta Orthop Scand* 1977;48:630–4.
31. Stolke D, Sollmann WP, Seifert V. Intra- and postoperative complications on lumbar disc surgery. *Spine* 1989;14:56–9.
32. Suk KS, Lee HM, Moon SH, et al. Recurrent lumbar disc herniation: results of operative management. *Spine* 2001;26:672–6.
33. Van Goethem JWM, Parizel PM, Van den Hauwe L, et al. Imaging findings in patients with failed back surgery syndrome. *J Belge Radiol* 1997;80:81–4.
34. Vishteh AG, Dickman CA. Anterior lumbar microdiscectomy and interbody fusion for the treatment of recurrent disc herniation. *Neurosurgery* 2001;48:334–7.
35. Waddell G, Kummel EG, Lotto WN, et al. Failed lumbar disc surgery and repeat surgery following industrial injuries. *J Bone Joint Surg [Am]* 1979;61:201–7.
36. Weber H. Lumbar disc herniation. A controlled, prospective study with ten years of observation. *Spine* 1983;8:131–40.
37. Yeung AT. The evolution of percutaneous spinal endoscopy and discectomy: state of the art. *Mt Sinai J Med* 2000;67:327–32.
38. Yeung AT, Tsou PM. Posterolateral endoscopic excision for lumbar disc herniation: surgical technique, outcome, and complications in 307 consecutive cases. *Spine* 2002;27:722–31.